" CEUS allows us to optimise our daily routines, to achieve the correct diagnosis faster and to improve solutions for unclear kidney cases"

CEUS

Contrast enhanced ultrasound (CEUS) **in aortic diseases**

Case studies courtesy of

Dirk-André Clevert, MD

Professor of Radiology Interdisciplinary Ultrasound-Center, Department of Clinical Radiology University of Munich-Grosshadern Campus, Germany

Abdominal Aortic Aneurysm (AAA)

Retroperitoneal Fibrosis (Ormond's disease)

Image Fusion (Abdominal Aortic Aneurysm)

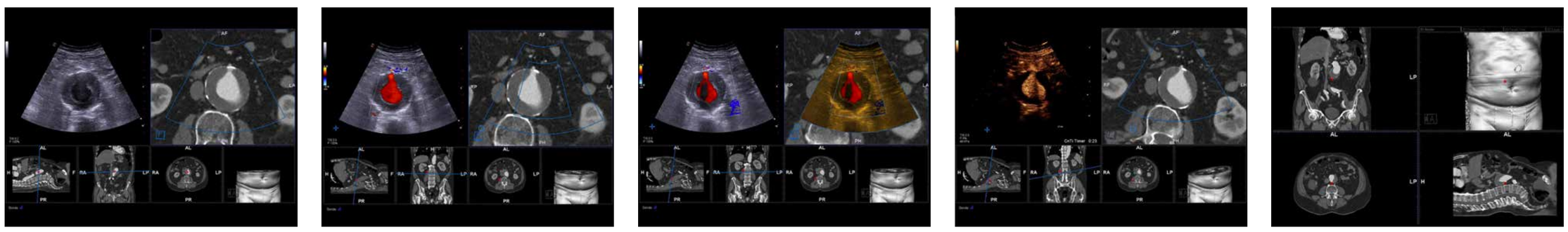

Normal Stentgraft after EVAR

Type 2 Endoleak over left lumbal artery

Type 2 Endoleak over inferior mesenteric artery (IMA)

N E V E R S T O P S E E I N G T H E U N S E E N .

esaote

Esaote S.p.A. - sole-shareholder company - Via Enrico Melen 77, 16152 Genova, ITALY, Tel. +39 010 6547 1, Fax +39 010 6547 275, info@esaote.com

CnTI™: The use of Contrast Agents in the USA is limited by FDA to the left ventricle opacification and to characterization of focal liver lesions Technology and features are system/configuration dependent. Specifications subject to change without notice. Information might refer to products or modalities not yet approved in all countries. Product images are for illustrative purposes only. For further details, please contact your Esaote sales representative.

1600026SMMK Ver. 01